



## PATIENT

Harvey Couch

## SPECIES

Feline

## BREED

DSH

## SEX

Male Neutered

## AGE

8 years

## WEIGHT

15lbs

## INTERPRETED BY

Maggie Machen Lamy,  
DVM, DACVIM  
(Cardiology)

## IMAGING PERFORMED BY

Dana Alterman,  
RDCS, LVT

## HOSPITAL NAME

Eubank Animal Clinic

## REFERRING VET

Dr. Schott

## INVOICE

28512

## DATE

1/23/23

## PRESENTING CLINICAL SIGNS

History: Previously diagnosed CHF, HCM and cardiomegaly.

Sedated with 100mg Gabapentin.

-Current medications: Furosemide 12.5mg ½ tab PO BID, Pimobendan, 1.25mg 1 tab PO BID, Clopidogrel 75mg ¼ tab PO SID.

## ECHOCARDIOGRAM FINDINGS

2D, m-mode, color flow and doppler imaging is available. The left ventricular wall is mildly increased in dimension. No LV dilation. Adequate systolic function. There is a diffusely hyperechoic endocardium consistent with fibrosis. The papillary muscles are asymmetric and remodeled. The mitral valve is normal with no MR. The left atrium is moderately dilated and bulbous in appearance. No obvious smoke. The right atrium is normal. Tricuspid valve is normal with trivial TR. The right ventricle appears normal. Blood flow through both the LVOT and RVOT is normal in velocity. No pericardial effusion seen. No pleural effusion. No obvious cardiac tumors.

## CARDIAC CHART

FELINE CARDIAC PARAMETERS	BODY WEIGHT (kg)	HR (BPM)	IVSd (cm) <small>(Moise, Pipers)</small>	LVIDd (cm) <small>(Moise, Pipers)</small>	LWVd (cm) <small>(Moise, Pipers)</small>	FS (%)	EF (%)
NORMAL PARAMETER	-----	150-240	0.35-0.55	<2 (mean 1.5)	3.5-0.55	35-67	80-100
PATIENT	6.8	NM	0.64	1.5	0.62	36	70
FELINE CARDIAC PARAMETERS	LA/AO <small>(Boon)</small>	LA/AO HEART BASE (Swe) <small>(Abbott)</small>	LA 2D short axis Base view (cm) <small>(Abbott)</small>		LVOT VEL  (m/s)	RVOT VEL  (m/s)	E max  (m/s)
NORMAL	<1.5	<1.3	<1.2		<1.6	<1.3	<0.9
PATIENT	NM	1.8	1.8		0.8	0.9	NM
<p><i>*Note: All measurements based upon multi-modal images and methods. An average value is reported.</i>                      Adapted from June Boon, Veterinary Echocardiography, 1998                      Abbott J &amp; MacLean H JVIM 2006;20: 111-119, Moise et al. Am J Vet Res 47:1476, 1986. Pipers et al. Am J Vet Res 40:882, 1979.</p>							

## INTERPRETATION OF THE FINDINGS & FURTHER RECOMMENDATIONS

The finding of left atrial enlargement in the face of only mild LV hypertrophy is most consistent with atypical Hypertrophic Cardiomyopathy; however, an Unclassified Cardiomyopathy (UCM), is also possible. Moderate left atrial dilation is present suggesting the risk for complication is high. No additional issues are identified.

Regardless of categorical classification, the finding of left atrial dilation confers risk for progression in the future. The history suggests CHF has been documented and if this is confirmed, certainly continued triple therapy is recommended. No obvious indication for additional medications at this time.



**PATIENT**

Harvey Couch

The long-term prognosis is poor once CHF has been diagnosed with an average survival time of <1 year. There will always remain risk for recurrent CHF, development of blood clots and/or sudden death in the future. Monitoring is certainly advised, particularly should any respiratory signs, collapse or significant lethargy be noted in the future.

**SPECIES**

Feline

Anesthetic risk is considered elevated, with high risk for fluid overload, spontaneous CHF, hypotension, etc. Judicious IV fluid rates are advised to avoid fluid overload. Drugs that stimulate heart rate should be avoided unless clinically necessary (glycopyrrolate, atropine). Avoid ketamine, telazol, acepromazine and Dexdomitor. A reasonable protocol includes opioid/benzodiazepine premedication, propofol induction, isoflurane maintenance.

**BREED**

DSH

**SEX**

Male Neutered

**PLAN**

Screening BP and T4 are recommended every 6 months. Continue Plavix, Lasix and Pimobendan as prescribed.

**AGE**

8 years

Monitor renal values and BP every 4-6 months lifelong.

A recheck echocardiogram is recommended in 6 months to assess progression.

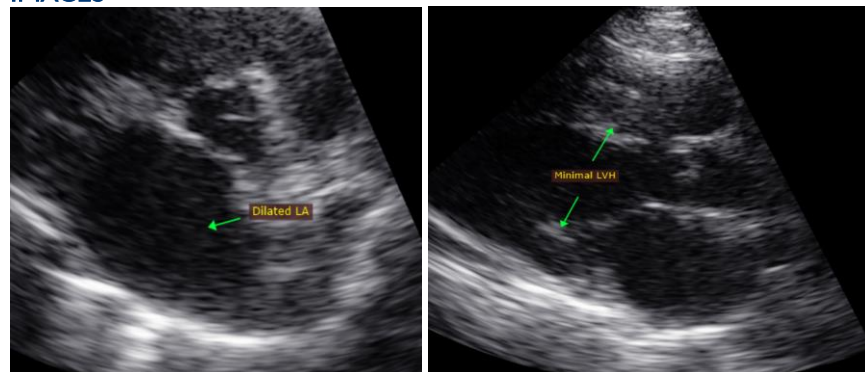
**WEIGHT**

15lbs

**IMAGES**

**INTERPRETED BY**

Maggie Machen Lamy,  
DVM, DACVIM  
(Cardiology)



**IMAGING PERFORMED BY**

Dana Alterman,  
RDCS, LVT

The information and recommendations provided are based on the images presented by the referring veterinarian. No evaluation can be communicated regarding pathology that was not visible in the image/video clips provided.

**HOSPITAL NAME**

Eubank Animal Clinic

Thank you for this referral. This report was generated using transcription software, and minor dictation errors may be present. If the clinical or image interpretation does not parallel your findings or if I can be of any further assistance, please contact me.

**REFERRING VET**

Dr. Schott

Maggie Machen Lamy, DVM  
Diplomate of the American College of Veterinary Internal Medicine (Cardiology)  
info@sonopath.com

**INVOICE**

28512

**DATE**

1/23/23